



PATIENT

Jango Fett Martin

SPECIES

Canine

BREED

LG

SEX

MN

AGE

7 years

WEIGHT

33.2 kg

INTERPRETED BY

Remo Lobetti, BVSc,
MMedVet (Med), PhD,
Dipl. ECVIM

IMAGING PERFORMED BY

Brent Crutchfield, DVM

HOSPITAL NAME

Treasure Coast Animal
Emergency

REFERRING VET

Dr Cail

INVOICE

303514

DATE

10/31/22

PRESENTING CLINICAL SIGNS

History: Possible thyroid mass. Previously diagnosed with Addison's disease.

Physical Examination: N/A.

Urinalysis: N/A

CBC: N/A.

Serum Biochemistry: N/A.

Radiographic Findings: N/A.

ULTRASONOGRAPHIC EXAMINATION OF THE ABDOMEN

Urinary System

Full urinary bladder with a normal thickness (0.2 cm) and appearance of the wall. Normal anechoic urine with no sediment evident. Uroliths (1.2 cm) present.

Normal trigone area, proximal urethra, and iliac blood vessels.

Normal iliac lymph nodes. Ureters not visualized.

Normal renal size (left 6.4 cm, right 6.2 cm), echogenic appearance, cortico-medullary differentiation, pelvis and capsule.

Reproductive System

Small hypoechogenic prostate (1.6 cm).

Adrenal Glands

Normal echogenic appearance and position but bilaterally narrow and small in size. Left 0.4 cm, right 0.44 cm.

Spleen

Normal size and echogenic appearance. Smooth homogenous parenchyma, regular curvilinear capsule, and normal vasculature. No evidence of inflammatory, neoplastic, infarction, or infiltrative changes noted

Liver

Normal size, echogenic appearance, portal markings, and curvilinear capsule. No nodules or masses evident. Full gall bladder containing normal anechoic bile. Normal thickness (0.1 cm) and echogenic appearance of the gall bladder wall. Normal bile duct.



PATIENT

Jango Fett Martin

SPECIES

Canine

BREED

LG

SEX

MN

AGE

7 years

WEIGHT

33.2 kg

INTERPRETED BY

Remo Lobetti, BVSc,
MMedVet (Med), PhD,
Dipl. ECVIM

IMAGING PERFORMED BY

Brent Crutchfield, DVM

HOSPITAL NAME

Treasure Coast Animal
Emergency

REFERRING VET

Dr Cail

INVOICE

303514

DATE

10/31/22

Gastrointestinal

Normal appearance of the gastro-esophageal junction, stomach, duodenum, small intestine, ileo-cecal junction, and colon with no loss of layering, normal wall thickness (stomach 0.47 cm, duodenum 0.45 cm, jejunum 0.39 cm, colon 0.14 cm) and peristaltic activity, and no distension of the lumen.

Pancreas

Normal size and echogenic appearance. Regular capsule. Normal echogenic appearance of the mesentery and fat surrounding the pancreas.

Free Abdomen

No mesenteric lymphadenomegaly.
No ascites.

Neck

Normal size and appearance of the thyroid glands. Right 2.1 cm.
Normal size and appearance of the parathyroid glands. Left 0.5 cm, right 0.4 cm.

ULTRASONOGRAPHIC FINDINGS

Primary findings:

- Urolith.
- Small adrenal glands.

Secondary findings:

- None.

INTERPRETATION OF THE FINDINGS & FURTHER RECOMMENDATIONS IMAGES

The appearance of the adrenal glands is consistent with the diagnosis of Addison's disease.

Further assessment would be urinalysis and urine culture.

Specific therapy would be dependent on an etiological diagnosis.



PATIENT

Jango Fett Martin

SPECIES

Canine

BREED

LG

SEX

MN

AGE

7 years

WEIGHT

33.2 kg

INTERPRETED BY

Remo Lobetti, BVSc,
 MMedVet (Med), PhD,
 Dipl. ECVIM

IMAGING PERFORMED BY

Brent Crutchfield, DVM

HOSPITAL NAME

Treasure Coast Animal
 Emergency

REFERRING VET

Dr Cail

INVOICE

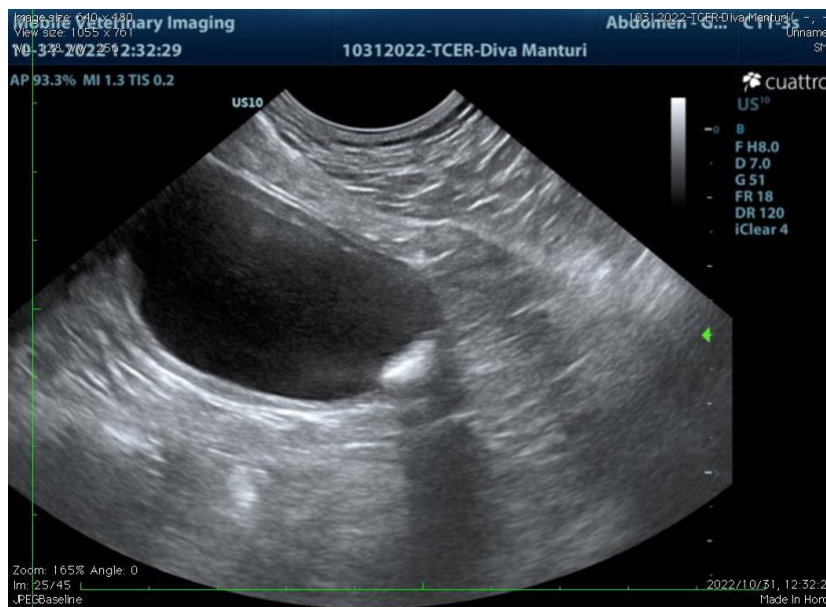303514

DATE

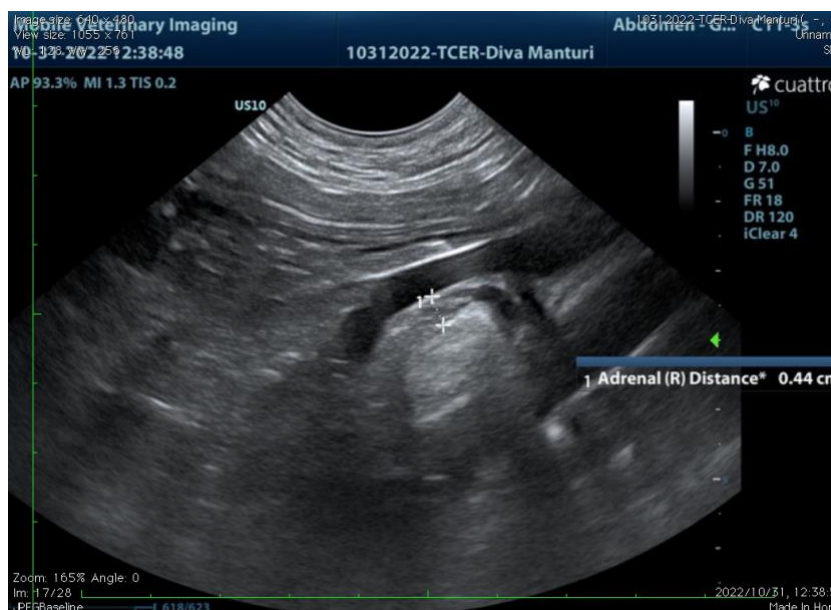10/31/22

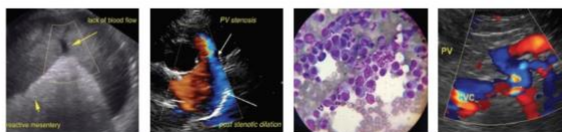
IMAGES

Urinary bladder



Right adrenal





PATIENT

Jango Fett Martin

SPECIES

Canine

BREED

LG

SEX

MN

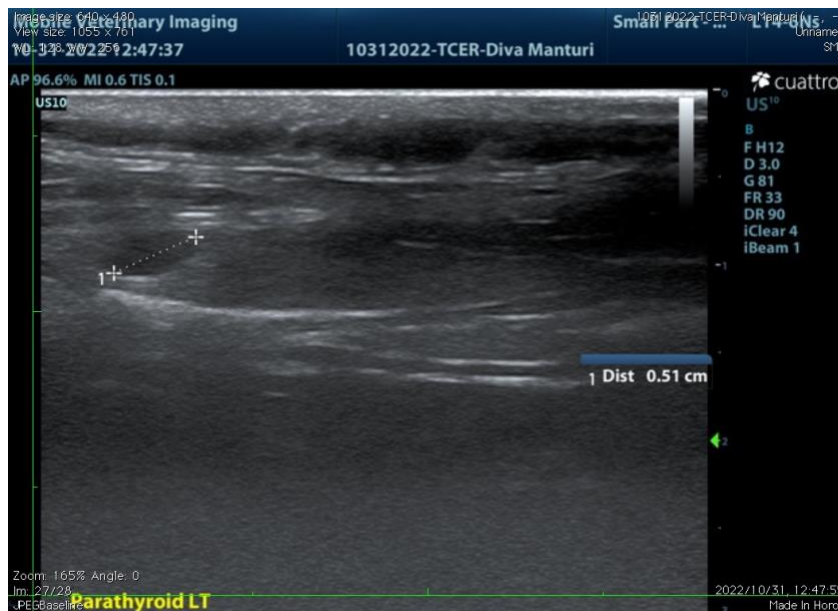
AGE

7 years

WEIGHT

33.2 kg

Left thyroid/parathyroid



INTERPRETED BY

Remo Lobetti, BVSc,
MMedVet (Med), PhD,
Dipl. ECVIM

The information and recommendations provided are based on the images presented by the referring veterinarian. No evaluation can be communicated regarding pathology that was not visible in the image/video clips provided.

Thank you for this referral. If the clinical or image interpretation does not parallel your findings or if I can be of any further assistance please contact me.

Remo Lobetti, BVSc, MMedVet (Med), PhD, Dipl. ECVIM (Internal Medicine)
rlobetti@mweb.co.za

IMAGING PERFORMED BY

Brent Crutchfield, DVM

HOSPITAL NAME

Treasure Coast Animal
Emergency

REFERRING VET

Dr Cail

INVOICE

303514

DATE

10/31/22